

## UP6-47 A new ureteric stent with silicone end piece to improve patient's comfort

Vogt B, France

Journal of Endourology.Sep 2018.ahead of print

Volume: 32 Issue S2: September 12, 2018, page A489-90.

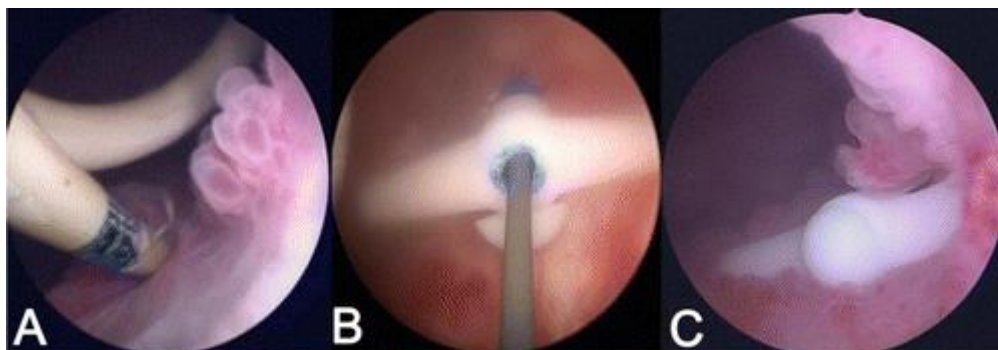
<http://doi.org/10.1089/end.2018.29043.abstracts>

**Introduction & Objective:** Double-pigtail stent intolerance reduces patient's quality of life. Ureteral obstruction caused by malignant compression may require indwelling stent. By decreasing the amount of material within the bladder, it should be possible to attenuate the symptoms linked to the stent. To minimize the amount of material left in the bladder, the evaluation of a new stent with a nonrefluxing silicone end piece was approved by French Ethical Committee and National Medicine Safety Agency.

**Methods:** Four patients had retrograde ureteric stenting for ureteric obstruction and complained strongly of symptoms associated with a double-pigtail stent. All patients agreed to be fitted with the new stent. The major characteristic of the ureteric stent was in the replacement of the bladder part of the double-pigtail stent with a nonrefluxing silicone end piece. A double-pigtail stent was sectioned perpendicularly, ensuring that the stent remains long enough to descend at the ureteral meatus. A silicone end piece was embedded at the bottom of the sectioned stent (Fig 1). The ureteral stent symptom questionnaire (USSQ) was prospectively administered to patients at baseline and Day 15 post-placement.

**Results:** The type of malignancy was prostatic cancer in two cases, colic cancer and, cervical cancer. All patients had received previous surgery and 3 had been treated with radiotherapy. Causes of ureteric obstruction were recurrent mass in 3 cases and post-operative radiosurgery in one case. The obstructions were in lower ureter in all cases. No dislodgment and no calcification were encountered after three months. All questionnaires were analyzed. The replacement of the double-pigtail stent with the new stent seems to decrease USSQ urinary symptom scores ( $36.5 \pm 4.7$  vs  $25.5 \pm 6.1$ ).

**Conclusions:** There was limitation to this study due to its low number of patients. But in this preliminary report, the use of the silicone end piece is possible and may be effective. By decreasing the amount of material in the bladder, it may be possible to attenuate the stent's symptoms. Further studies in a randomized, controlled trial should confirm the improvements in treatment reported here.



**Figure 1.** (A) Double-pigtail stent with inflammation in endoscopic appearance. (B) Silicone end piece with guidewire. (C) Silicone end piece in ureteral meatus.